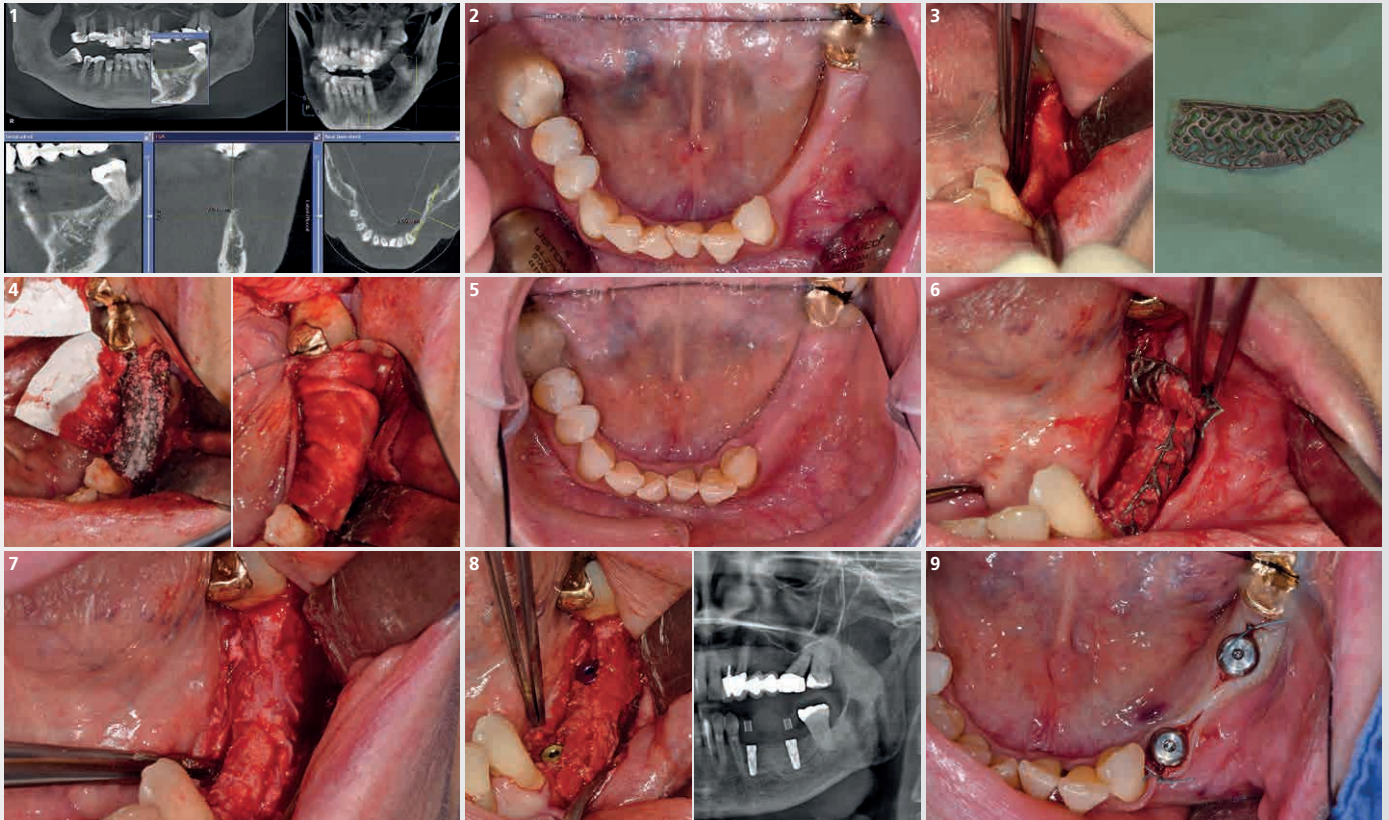


# Horizontal/Vertical Defect (3 teeth gap) Mandible

Dr. Alexander Volkmann



1 CBCT showing the horizontal and minor vertical buccal bone defect

2 Clinical situation before the augmentation

3 After opening the flap with a ridge incision, Yxoss CBR® is tested and the flap is adapted to ensure the complete soft tissue closure

4 Autologous bone is removed with a safescraper® and mixed 50:50 with Geistlich Bio-Oss®. The Yxoss CBR® is fixed with 2 screws (1,7mm) and totally covered with a Geistlich Bio-Gide® membrane

5 After 4 months, the horizontal augmentation is evident comparing to the initial situation

6 The 3D titanium scaffold is removed after cutting the breaking points

7 The buccal bone was reconstructed after regenerative procedure

8 The implants were placed (34 and 36) and surrounded by autologous bone chips removed from the adjacent area. Radiographic image after implant placement

9 Orthodontic treatment was performed and the implant cover was placed for soft tissue modelling after 6 months.